

F-18 FDG PET/CT Images of a Patient with Myelodisplastic Syndrome and Systemic Infection Mimicking Lymphoma

Zehra Pınar KOÇ¹ Pınar Pelin ÖZCAN² Tahsin ÇOLAK³ Gökçe YAVAN⁴

¹Mersin University, Faculty of Medicine, Department of Nuclear Medicine, Mersin, Turkey, zehrapinarkoc@gmail.com

²Mersin University, Faculty of Medicine, Department of Nuclear Medicine, Mersin, Turkey, ppelinozcan@gmail.com

³Mersin University, Faculty of Medicine, Department of General Surgery, Mersin, Turkey, colaktahsin@yahoo.com

⁴Mersin University, Faculty of Medicine, Department of Nuclear Medicine, Mersin, Turkey, gyavan95@gmail.com

Cite this study: Koc, Z. P., Ozcan, P. P., Colak, T. & Yavan, G. (2022). F-18FDG PET/CT Images of a Patient with Myelodisplastic Syndrome and Systemic Infection Mimicking Lymphoma. Molecular Oncologic Imaging, 2(1), 8-9

Keywords

Myelodisplastic syndrom
Lymphoma
FDG PET/CT

Abstract

Although F-18 FDG PET/CT is an accurate imaging modality in the diagnosis of Lymphoma there are conflicting pathologies as well. By this case report we want to demonstrate a false positive cause Lymphoma results shown by F-18 FDG PET/CT of a patient with final diagnosis of Myelodisplastic syndrome and Systemic Infection.

Research Article

Received: 08.01.2022

Accepted: 19.02.2022

Published: 15.03.2022

1. Case report

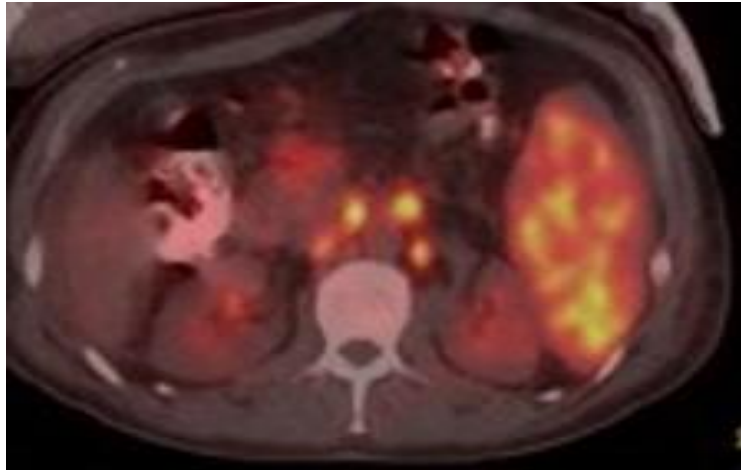


Figure 1. Forty two years old male patient who attended hospital for abdominal pain and ultrasonography results revealed caecal fistula and severe abdominal enlarged lymph nodes and splenomegaly. The F18 FDG PET/CT showed significant FDG uptake at the abdominal sites (bowel Wall, lymph nodes and spleen) that were determined by sonography.

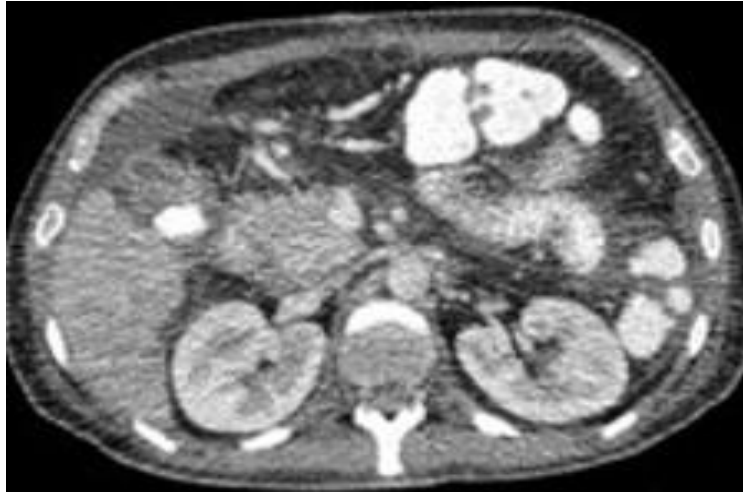

Figure 2. Biopsy of the bowel and splenectomy results revealed infection and bone marrow biopsy diagnosis was Myelodysplastic syndrome. The abdominal pathologic findings were disappeared at the third month follow up diagnostic CT.

2. Discussion

There are limited number of cases with F-18 FDG PET/CT findings of the patients the diagnosis of Myelodysplastic syndrome (1). Previous reports showed bone marrow FDG uptake related to Myelodysplastic syndrome involvement (2). In a previous case series of two patients with additional Behçet Disease revealed ceacum infiltration as in this case (3). This is presentation of a case with false positivity for Lymphoma in F-18 FDG PET/BT with final diagnosis of severe infection and Myelodysplastic syndrome.

Conflict of Interest

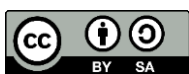No conflict of interest was declared by the authors.

Author Contributions

Concept: Z.P.K.; Design: Z.P.K., G.Y.; Supervision: Z.P.K., P.P.O., T.Ç.; Funding: Z.P.K.; Data Collection and/or Processing: Z.P.K.; Analysis and/or Interpretation: Z.P.K., P.P.O.; Literature Review: Z.P.K.; Writer: Z.P.K., G.Y.

References

1. Inoue, K., Okada, K., Harigae, H., Taki, Y., Goto, R., Kinomura, S., Kato, S., Kaneta, T., & Fukuda, H. (2006). Diffuse bone marrow uptake on F-18 FDG PET in patients with myelodysplastic syndromes. *Clinical nuclear medicine*, 31(11), 721–723. <https://doi.org/10.1097/01.rlu.0000242685.55001.67>.
2. Imataki, O., Uchida, S., Shiroshita, K., Kida, J., & Uemura, M. (2015). Marked Hematopoiesis Masquerading Multiple Bone Metastasis in a Lung Cancer Patient with Myelodysplastic Syndrome. *Clinical nuclear medicine*, 40(7), 574–575. <https://doi.org/10.1097/RLU.0000000000000698>.
3. Ito, K., & Kubota, K. (2016). 18F-FDG PET/CT Findings in Two Cases with Myelodysplastic Syndrome Accompanied by Behçet's Disease. *Clinical nuclear medicine*, 41(8), e392–e393. <https://doi.org/10.1097/RLU.0000000000001198>.



© Author(s) 2022. This work is distributed under <https://creativecommons.org/licenses/by-sa/4.0/>