

## Metastatic Brain Lesions of Colon Carcinoma on F-18 Fluorodeoxyglucose (FDG) Positron Emission Tomography/Computed Tomography (PET/CT)

Zehra Pınar KOÇ<sup>1</sup> Pınar Pelin ÖZCAN<sup>2</sup> Hamide SAYAR<sup>3</sup>

<sup>1</sup>Mersin University, Faculty of Medicine, Department of Nuclear Medicine, Mersin, Turkey, zehrapinarkoc@gmail.com

<sup>2</sup>Mersin University, Faculty of Medicine, Department of Nuclear Medicine, Mersin, Turkey, ppelinozcan@gmail.com

<sup>3</sup>Mersin University, Faculty of Medicine, Department of Pathology, Mersin, Turkey, hamidesayar@mersin.edu.tr

Cite this study: Koc, Z. P., Ozcan, P. P. & Sayar, H. (2022). Metastatic Brain Lesions of Colon Carcinoma on F-18 Fluorodeoxyglucose (FDG) Positron Emission Tomography/Computed Tomography (PET/CT). Molecular Oncologic Imaging, 2(2), 12-14

### Keywords

Metastasis  
Brain  
Colon Carcinoma  
FDG PET/CT

### ABSTRACT

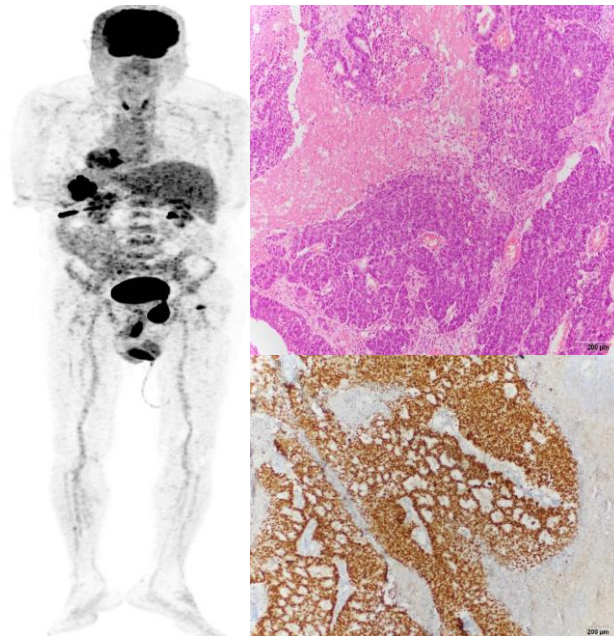
Metastatic brain tumors of colon carcinoma usually present with multiorgan metastasis and are associated with worse prognosis. The diagnostic imaging modality of brain metastasis is MR thus there are limited data about FDG PET/CT appearance of these tumors. This is the report of three cases with pathological diagnoses of brain metastasis of colon metastasis with FDG PET/CT images.

### Research Article

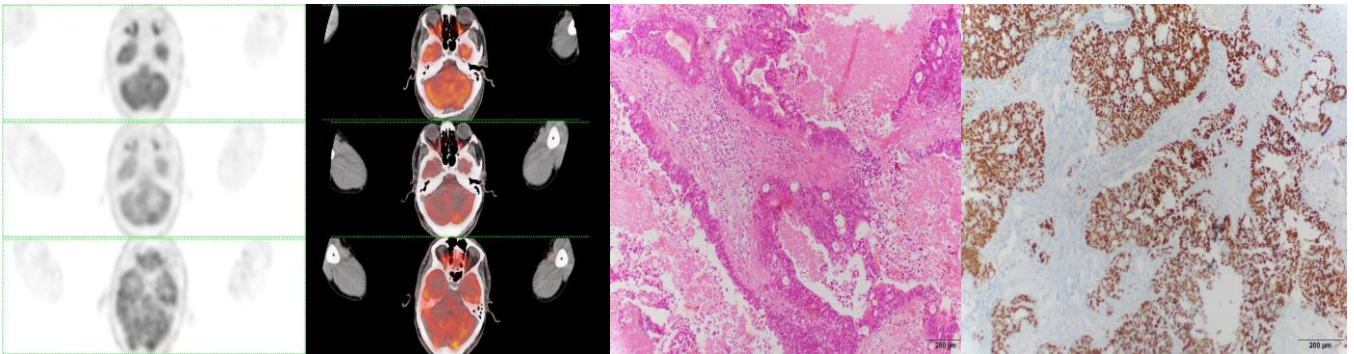
Received: 02.06.2022

Accepted: 30.06.2022

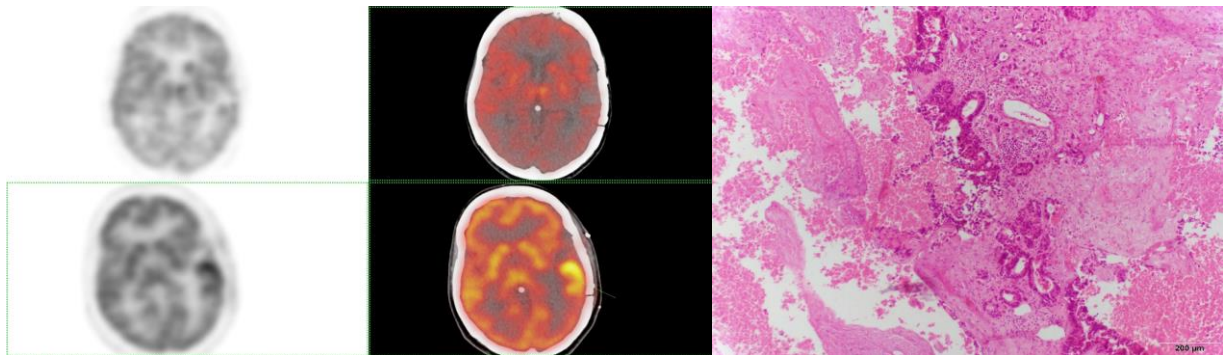
Published: 31.07.2022



**Figure 1.** Seventy nine years old male patient presented with hemorrhagic brain metastasis of unknown primary tumor which was determined by FDG PET/CT. The multiple intensity projection and transaxial PET/CT fusion data showed primary tumor at splenic flexure (Figure 1a) as well as postoperative changes in the left temporal lobe. Pathology images of the patient verified the primary colon carcinoma metastasis with hematoxylin and eosin and immunohistochemical staining respectively (Figure 1b-c).



**Figure 2.** Sixty six years old male patient with diagnosed with metastatic colon carcinoma was incidentally diagnosed with brain metastasis at FDG PET/CT follow up. The transaxial fusion PET/CT images show the follow up and postoperative changes at the left cerebellum (Figure 2a-b). The patient also had hypermetabolic thyroid nodule and metastatic pulmonary lesions with the follow-up of as long as 30 months. The pathology results also demonstrated brain metastasis of colon carcinoma with hematoxylin and eosin and immunohistochemical staining respectively (Figure 2d-c).



**Figure 3.** Forty six years old female patient with intracranial bleeding and left parietal metastasis of an unknown primary tumor. The PET/CT transaxial brain images showed hypermetabolic brain lesion and postoperative changes in the follow-up (5 months) (Figure 3a-b). The patient also presented with severe lymph node and liver metastasis as well as a primary tumor at the sigmoid colon. Pathology results showed colon metastasis in the brain parenchyma with hematoxylin and eosin (Figure 3c).

## Discussion

Previous literature data indicate the lowest survival for brain metastasis of colon carcinoma compared to the other metastatic sites (1, 2). However, there are reported cases with prolonged survival with oligo metastatic disease with a specific treatment approach (3). A rare case was presented with 54 months of follow-up results and Methionine PET/CT follow up (4). However, there are limited number of patients with PET/CT imaging because MR is the choice for imaging of brain tumors due to the limitations of FDG PET/CT imaging with high background activity in the brain. This is the most extensive series reported with the PET/CT images of the metastatic brain lesions of colon tumors.

## Conflict of Interest

No conflict of interest was declared by the authors.

## Author Contributions

Concept: Z.P.K.; Design: Z.P.K.; Supervision: Z.P.K., P.P.O., H.S.; Funding: Z.P.K.; Data Collection and/or Processing: Z.P.K., H.S.; Analysis and/or Interpretation: Z.P.K.; Literature Review: Z.P.K.; Writer: Z.P.K.

**REFERENCES**

1. Stewart, C. L., Warner, S., Ito, K., Raoof, M., Wu, G. X., Kessler, J., Kim, J. Y., & Fong, Y. (2018). Cytoreduction for colorectal metastases: liver, lung, peritoneum, lymph nodes, bone, brain. When does it palliate, prolong survival, and potentially cure?. *Current problems in surgery*, 55(9), 330–379. <https://doi.org/10.1067/j.cpsurg.2018.08.004>
2. Sperduto, P. W., Chao, S. T., Sneed, P. K., Luo, X., Suh, J., Roberge, D., Bhatt, A., Jensen, A. W., Brown, P. D., Shih, H., Kirkpatrick, J., Schwer, A., Gaspar, L. E., Fiveash, J. B., Chiang, V., Knisely, J., Sperduto, C. M., & Mehta, M. (2010). Diagnosis-specific prognostic factors, indexes, and treatment outcomes for patients with newly diagnosed brain metastases: a multi-institutional analysis of 4,259 patients. *International journal of radiation oncology, biology, physics*, 77(3), 655–661. <https://doi.org/10.1016/j.ijrobp.2009.08.025>
3. Morinaga, N., Tanaka, N., Shitara, Y., Ishizaki, M., Yoshida, T., Kouga, H., Wakabayashi, K., Fukuchi, M., Tsunoda, Y., & Kuwano, H. (2016). Ten-Year Survival of a Patient Treated with Stereotactic Gamma Knife Radiosurgery for Brain Metastases from Colon Cancer with Ovarian and Lymph Node Metastases: A Case Report. *Case reports in gastroenterology*, 10(1), 199–206. <https://doi.org/10.1159/000445976>.
4. Kimura, M., Tanishima, H., Tatsubayashi, T., Iwakura, S., Tominaga, T., & Horiuchi, T. (2017). Gan to kagaku ryoho. *Cancer & chemotherapy*, 44(12), 1388–1390



© Author(s) 2022. This work is distributed under <https://creativecommons.org/licenses/by-sa/4.0/>