Molecular Oncologic Imaging

http://publish.mersin.edu.tr/index.php/moi/index

Abdominal Vasculitis Determined by Fluorodeoxyglucose Positron Emission Tomography/Computed Tomography

Zehra Pınar KOÇ[1] Pınar Pelin ÖZCAN[2] Nurdan ORUÇOĞLU[3] Hamide SAYAR[4]

[1]*Mersin University, Faculty of Medicine, Department of Nuclear Medicine, Mersin, Turkey, zehrapinarkoc@gmail.com*
[2]*Mersin University, Faculty of Medicine, Department of Nuclear Medicine, Mersin, Turkey, ppelinozcan@gmail.com*
[3]*Mersin University, Faculty of Medicine, Department of Romatology, Mersin, Turkey, norucoglu@mersin.edu.tr*
[4]*Mersin University, Faculty of Medicine, Department of Pathology, Mersin, Turkey, hamidesayar@mersin.edu.tr*

Cite this study: Koc, Z. P., Ozcan, P. P., Orucoglu, N. & Sayar, H. (2022). Abdominal Vasculitis Determined by Fluorodeoxyglucose Positron Emission Tomography/Computed Tomography. Molecular Oncologic Imaging, 3(1), 1-5

Keywords
Abdominal
Vasculitis
FDG PET/CT

Research Article
Received: 30.05.2022
Accepted: 15.07.2022
Published: 31.07.2022

ABSTRACT

Aim: The retrospective evaluation of abdominal vasculitis detected by FDG PET/CT examinations.

Materials and Methods: Seven patients (3 Female, 4 Male, 26-72 years old) were subjects of this study. The images of the patients as well as clinic and pathologic features were analyzed retrospectively.

Results: The determination of the abdominal vasculitis is possible as a primary diagnosis or incidentally during an investigation of a known another disease (malignancy).

Conclusion: This case series demonstrates the significance of this clinical entity as well as the associated malignancy with this disease by FDG PET/CT.

1. Introduction

The chemical properties of the FDG allow the PET/CT imaging to demonstrate both malignant tumors and infectious and inflammatory diseases and conditions. Previous observations about the imaging utility of FDG PET/CT in vasculitis were not limited to the case reports. The diagnostic performance of FDG PET/CT in vasculitis is accepted which was shown by large series (1, 2). The aim of this retrospective analysis of the patients with incidentally detected abdominal vasculitis was to determine the clinical significance of this finding as well as to determine associated malign conditions.

2. Materials and Methods

Seven patients (3 Female, 4 Male, 26-72 years old) were the subjects of this study. The F-18 FDG PET/CT imaging was performed to the patients in order to determine infection-inflammation or staging, restaging a known primary malignant tumor. The images of the patients as well as clinic and pathologic features were analyzed retrospectively.

3. Results

The demographic and clinical features of the patients are summarized in table 1. Abdominal aortitis was present in all patients and disseminated vasculitis was observed in two (Figure 1, 2). Three patients had additional malignant tumors and one of them presented with three different tumors (Figure 3). Three patients also had spleen, lymph node and muscle involvements among whom one patient additionally presented with vena cava thrombus (Figure 4). One patient with disseminated form vasculitis died during the disease course (Figure 5). One patient only had pathologically documented Giant cell arteritis and the other two were confirmed to have other inflammatory pathology results.

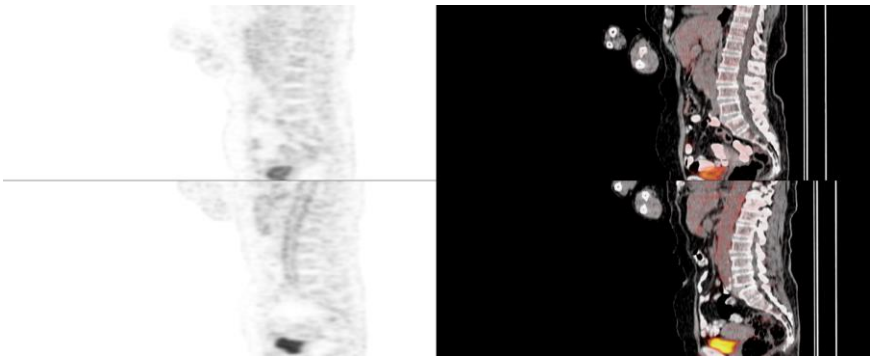

Figure 1. 65 years old female patient with suspicion of malignancy who had cystic lesion of pancreas was referred. The PET/CT images revealed severe vasculitis involvement of carotid, subclavian, thoracic and abdominal aorta.

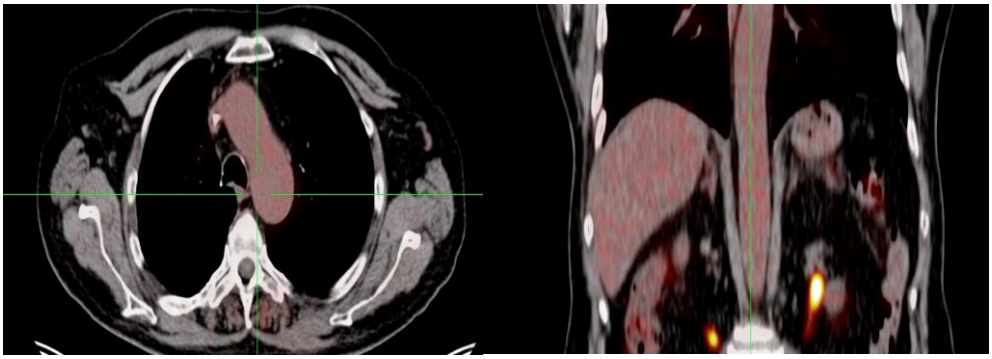

Figure 2. 67 years old male patient with diagnosis of adenoid cystic carcinoma of the lung and left submandibular gland. The patient was referred for treatment response evaluation and the PET/CT images showed severe abdominal vasculitis as well as muscular involvement.

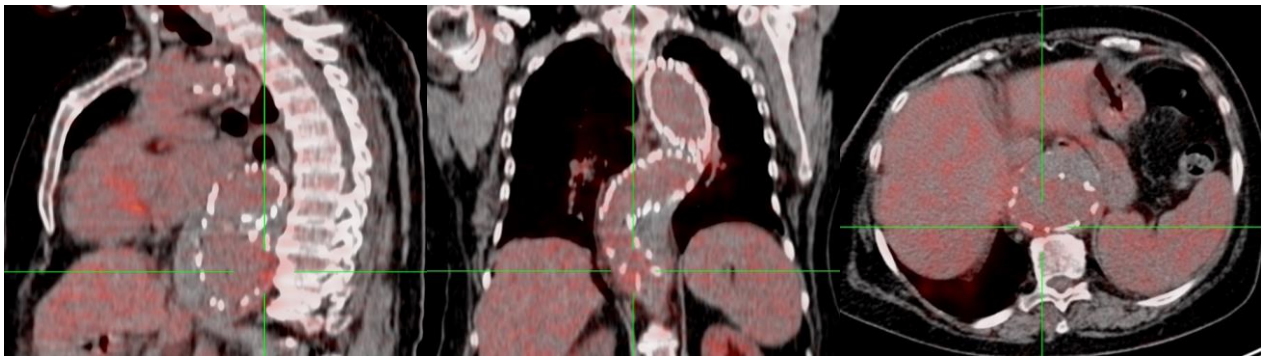

Figure 3. Seventy-one years old female patient with the previous diagnosis of endometrium (Grade 2, Endometrioid carcinoma), oncocytic carcinoma of the right parotid and bilateral breast carcinoma (Lobular carcinoma)is presented. Additionally, history of traumatic aorta dissection operation. After the operation of the secondary malignancy (parotidectomy) the patient was referred for staging/restaging to the FDG PET/CT (Figure 3). The imaging findings demonstrated vasculitis with FDG accumulation at the left subclavian artery as well as previously operated and enlarged aorta from the level of the subclavian artery to the abdomen. Additional to these findings suspicion of the third malignancy in breast tissue was addressed and operations revealed lobular breast carcinoma afterward.

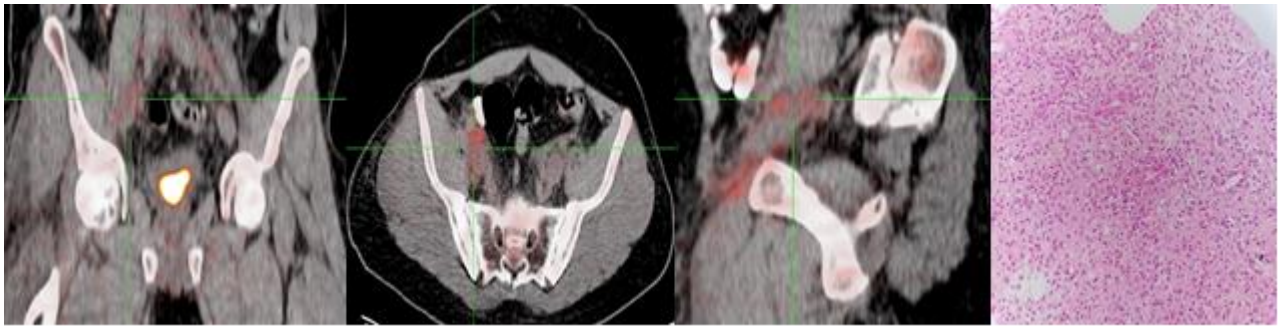

Figure 4. 26 years old male patient referred to FDG PET/CT for investigation of inflammation, infection or vasculitis. The imaging verified the clinical condition as vasculitis of the vena cava as well as right common iliac femoral vessels inflammatory FDG accumulation and thrombosis. Pathology results confirmed inflammation.

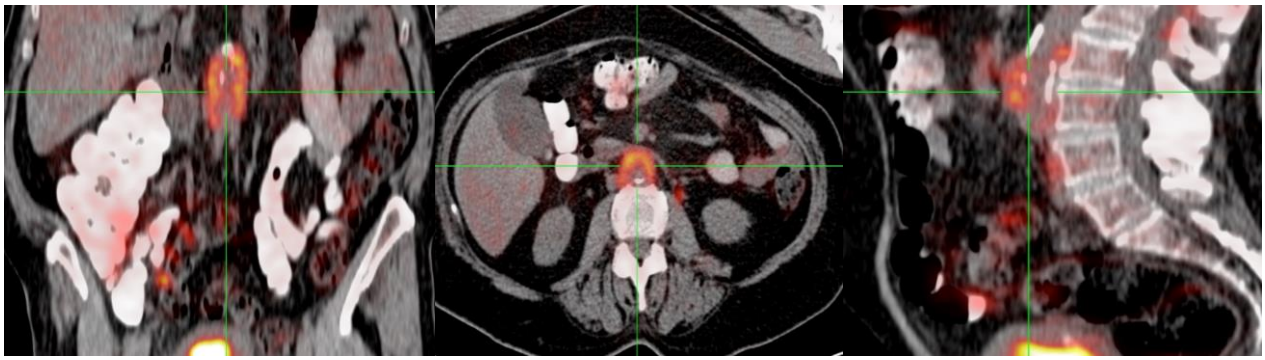

Figure 5. Fifty-seven years old male with suspicious lesions around the thoracic vertebra bodies: metabolic characterization by the PET/CT imaging showed increased FDG accumulations at these lesions as well as abdominal aorta vasculitis.

Table 1. The diagnostic features of the subjects.

Patient No	Age	Gender	PET/CT	Pathology	Mortality
1	67	M	Disseminated aorta and branches and muscle	Adenoid cystic carcinoma	Ex
2	65	F	Disseminated aorta and branches	Giant cell arteritis	-
3	51	F	Spleen, lymph node, abdominal aorta	Panniculitis	-
4	26	M	Spleen, lymph node, vena cava thrombus, abdominal aorta involvement	-	
5	57	M	Abdominal aorta and iliac arteries	Inflammation	-
6	72	M	Abdominal aorta and iliac arteries	Lung adenocarcinoma	-
7	71	F	Subclavian artery and aorta	Endometrium, lobular breast and parotid oncocytic carcinoma	-

4. Discussion

Among the patients in this series one patient had triple malignancies in the body and other cases presented with findings associated with vasculitis or diseases associated with vasculitis. As previously documented in the literature FDG PET/CT demonstrated vasculitis associated inflammation (1, 2). The vasculitis might be in the form of large, medium, small and variable vessel involvement. Vasculitis has either vascular or extravascular involvement and in some cases both of them. Large cell vasculitis usually presents with aorta involvement, which

was the case in our patients. Additionally, extravascular involvement might accompany some of them, but these were not pathologically confirmed.

In a previous case series including the significant number of patients sixty six (93%) of the patients presented with positive F-18 FDG PET/CT findings (1). Most of these patients had additional spleen and bone marrow uptake which might be attributed to systemic inflammation but we do not know the exact etiology in some instances.

The vasculitis in this group of patients were also severe and complicated, especially in one case. The prognostic value of the FDG PET/CT for complication-aortic events was previously documented in a series of the patients with Giant cell arteritis (4).

In a case report, there was o potential implication of Ga-68 FAPI PET/CT in vasculitis in compared with FDG PET/CT. (5) This issue needs to be evaluated with larger series.

Abdominal vasculitis is a relatively rare condition documented in this case series. The patients in this series usually were not referred for a known inflammatory condition and evaluation of vasculitis. However, some of the patients in this series had several malignancies with exceptional triple malignancy and metastatic or secondary malignancy in another patient. The association of the malignancy and vasculitis is not clear in the previous literature.

There is a limited number of abdominal vasculitis patients with PET/CT images in the literature. There is a report of case in the literature with rare abdominal and all branch involvement with PET/CT results (3).

The previous series including Giant cell arteritis patients with PET/CT results showed that this diagnosis is associated with aortitis findings (6). Another study indicated PET/CT based activity scoring might distinguish active Large Vessel Vasculitis from the inactive but cannot predict relapses (7). Artificial intelligence was implemented in a previous series which has been shown to support the diagnosis (8). Additionally, the disease regression was reported after treatment by FDG PET/CT (9). Vasculitis in conjunction with a primary condition was documented previously (9). However, this is a unique specific series with PET/CT results.

The limitations of this study are the limited number of patients and documentation of the vasculitis in all cases. However due to the malignancies of the patients or the suspicion of malignancy, vasculitis was not considered the primary problem of the patients.

Conflict of Interest

No conflict of interest was declared by the authors.

Financial Disclosure

The authors declared that this study has received no financial support.

Author Contributions

Concept: Z.P.K.; Design: Z.P.K.; Supervision: Z.P.K., P.P.O., H.S.; Funding: Z.P.K.; Data Collection and/or Processing: Z.P.K., N.O., H.S.; Analysis and/or Interpretation: Z.P.K.; Literature Review: Z.P.K.; Writer: Z.P.K.

REFERENCES

1. Galli, E., Muratore, F., Mancuso, P., Boiardi, L., Marvisi, C., Besutti, G., Spaggiari, L., Casali, M., Versari, A., Giorgi Rossi, P., & Salvarani, C. (2022). The role of PET/CT in disease activity assessment in patients with large vessel vasculitis. Rheumatology (Oxford, England), keac125. Advance online publication. https://doi.org/10.1093/rheumatology/keac125
2. Chen, Z., Zhao, Y., Wang, Q., Li, Y., Li, H., & Zhou, Y. (2022). Imaging features of 18F-FDG PET/CT in different types of systemic vasculitis. Clinical rheumatology, 41(5), 1499–1509. https://doi.org/10.1007/s10067-021-06039-1.
3. Bonnefoy PB, Goutte J, Jacquet-Francillon N, Habouzit V, Prevot N. Usual and Rare Abdominal Location of Giant Cell Arteritis Diagnosed and Follow-up With 18F-FDG PET/CT. Clin Nucl Med. 2021 Apr 1;46(4):e218-e220.
4. Wu, S., Pang, Y., Zhao, L., Zhao, L., & Chen, H. (2021). 68Ga-FAPI PET/CT Versus 18F-FDG PET/CT for the Evaluation of Disease Activity in Takayasu Arteritis. Clinical nuclear medicine, 46(10), 847–849. https://doi.org/10.1097/RLU.0000000000003692
5. Espitia, O., Blonz, G., Urbanski, G., Landron, C., Connault, J., Lavigne, C., Roblot, P., Maillot, F., Audemard-Verger, A., Artifoni, M., Durant, C., Guyomarch, B., Hamidou, M., Magnant, J., Agard, C., & French Study Group for Large Vessel Vasculitis (GEFA) (2021). Symptomatic aortitis at giant cell arteritis diagnosis: a prognostic factor of aortic event. Arthritis research & therapy, 23(1), 14. https://doi.org/10.1186/s13075-020-02396-5

6. Mestre-Torres, J., Martínez-Valle, F., Gabaldón, A., Simó-Perdigó, M., Salcedo-Allende, M. T., Navales-Mateu, I., & Solans-Laqué, R. (2022). Are Temporal Artery Biopsy Findings Related to PET/CT Findings in Giant Cell Arteritis?. Clinical nuclear medicine, 47(5), 387–393. https://doi.org/10.1097/RLU.0000000000004097.
7. Galli, E., Muratore, F., Mancuso, P., Boiardi, L., Marvisi, C., Besutti, G., Spaggiari, L., Casali, M., Versari, A., Giorgi Rossi, P., & Salvarani, C. (2022). The role of PET/CT in disease activity assessment in patients with large vessel vasculitis. Rheumatology (Oxford, England), keac125. Advance online publication. https://doi.org/10.1093/rheumatology/keac125.
8. Duff L, Scarsbrook AF, Mackie SL, Frood R, Bailey M, Morgan AW, Tsoumpas C. A methodological framework for AI-assisted diagnosis of active aortitis using radiomic analysis of FDG PET-CT images: Initial analysis. J Nucl Cardiol. 2022 Mar 23. doi: 10.1007/s12350-022-02927-4.
9. Martínez-Rodríguez, I., Jiménez-Alonso, M., Quirce, R., Jiménez-Bonilla, J., Martínez-Amador, N., De Arcocha-Torres, M., Loricera, J., Blanco, R., González-Gay, M. Á., & Banzo, I. (2018). 18F-FDG PET/CT in the follow-up of large-vessel vasculitis: A study of 37 consecutive patients. Seminars in arthritis and rheumatism, 47(4), 530–537. https://doi.org/10.1016/j.semarthrit.2017.08.009
10. Sangolli, P. M., & Lakshmi, D. V. (2019). Vasculitis: A Checklist to Approach and Treatment Update for Dermatologists. Indian dermatology online journal, 10(6), 617–626. https://doi.org/10.4103/idoj.IDOJ_248_18.

© Author(s) 2022. This work is distributed under https://creativecommons.org/licenses/by-sa/4.0/