

Ga-68 PSMA PET-CT in Initial Staging First Line Imaging of Prostate Cancer: The Clinical Impact of Oligometastatic Disease

Pınar Pelin ÖZCAN¹ Zehra Pınar KOÇ² Vehbi ERÇOLAK³ Zeynep Selcan SAĞLAM⁴ Gökçe YAVAN⁵ Murat BOZLU⁶ Mesut TEK⁷ Erdem AKBAY⁸

¹Mersin University, Faculty of Medicine, Department of Nuclear Medicine, Mersin, Turkey, ppelinozcan@gmail.com

²Mersin University, Faculty of Medicine, Department of Nuclear Medicine, Mersin, Turkey, zehrapinarokoc@gmail.com

³Mersin University, Faculty of Medicine, Department of Oncology, Mersin, Turkey, vehbiercolak@mersin.edu.tr

⁴Mersin University, Faculty of Medicine, Department of Nuclear Medicine, Mersin, Turkey, z.selcansaglam@gmail.com

⁵Mersin University, Faculty of Medicine, Department of Nuclear Medicine, Mersin, Turkey, gyavan95@gmail.com

⁶Mersin University, Faculty of Medicine, Department of Urology, Mersin, Turkey, muratbozlu@mersin.edu.tr

⁷Mersin University, Faculty of Medicine, Department of Urology, Mersin, Turkey, mesuttekk@mersin.edu.tr

⁸Mersin University, Faculty of Medicine, Department of Urology, Mersin, Turkey, erakbay@mersin.edu.tr

Cite this study: Ozcan, P. P., Koc, Z. P., Ercolak, V., Saglam, Z. S., Yavan, G., Bozlu, M., Tek, M., & Akbay, E. (2022). Ga-68 PSMA PET-CT in Initial Staging-First-Line Imaging of Prostate Cancer: The Clinical Impact of Oligometastatic Disease. *Molecular Oncologic Imaging*, 2(2), 15-24

Keywords

68 Ga PSMA PET-CT
Prostate cancer
Initial staging

Research Article

Received: 06.06.2022
Accepted: 01.07.2022
Published: 31.07.2022

ABSTRACT

Background: Imaging plays an essential role in the evaluation of prostate cancer patients. In recent years, much attention has been focused on 68Ga-PSMA PET-CT in prostate cancer patients and has been widely used for staging, especially biochemical relapse-restaging and therapy response for these patients. This study aimed to evaluate 68 Ga PSMA PET-CT imaging in initial staging-first line imaging of prostate cancer from low to high risk patients.

Materials & Methods: Patients with low, intermediate and high risk newly diagnosed prostate cancer referred for initial staging of prostate cancer were included in the study. Histopathology and follow-up clinical and radiological information after PET/CT scanning served as the standard of reference.

Results: The study included a total of 176 consecutive patients underwent 68 Ga PSMA PET-CT for initial staging with prostate cancer final histopathology result. The study included a total of 27 low-risk, 35 intermediate risk, and 114 high-risk patients SUVmax in the primary tumor was correlated significantly with PSA levels and patient risk group. Mean SUVmax values of the primary prostate lesion were 16.6 %, 25.8 % and 35.2 % in low, intermediate and high risk patients, respectively. Oligometastases were detected in low and intermediate groups in similar proportions and slightly less in high risk patients (22 %, 22.8 % and 15.7 % in low, intermediate and high risk patients respectively), In contrast, in low, intermediate, and high-risk patients, multiple metastases were detected significantly higher in high-risk group patients (3.7 %, 8.6 %, and 52.6 %, respectively).

Conclusions: Oligometastases were detected with a relatively high rate in low- and intermediate-risk group patients. Ga-68 PSMA PET-CT imaging in newly diagnosed prostate cancer patients, even in low-risk patients, was quite valuable in the current study. Ga-68 PSMA imaging should be done in all risk groups as a first-line imaging modality. This finding should be supported by other studies with the large number of patients.

1. Introduction

68 Gallium Prostate Specific Membrane Antigen Positron Emission Tomography-Computed Tomography (68 Ga PSMA PET-CT) imaging is the most exciting imaging modality in prostate cancer patients in recent years. It has gained acceptance as a highly sensitive and specific imaging modality for evaluating extent of the disease (1). The initial work-up of high-risk prostate cancer patients should include conventional imaging procedures such as pelvic magnetic resonance imaging (MRI), computerized tomography (CT) and bone scintigraphy (BS), according to the 2017 European Association of Urology guidelines (2). Due to the low sensitivity of radiological examinations used routinely in the clinical imaging of prostate cancer, expected success can not be reached in staging and restaging (3). In Nuclear Medicine applications, while PET-CT with FDG is successfully in imaging most solid tumors, it did not show the same success in prostate cancer (4). However in several reports 68 Ga PSMA PET-CT was also superior to conventional imaging for detecting metastases in initial staging (5-10). Ga-68 PSMA PET/CT has recently gained acceptance as a highly sensitive and specific imaging modality for restaging in the settings of biochemical recurrence. The diagnosis of local-advanced disease or the presence of metastases in prostate cancer determines the indication for surgical treatment. The optimal imaging modality is still underdebate in the initial staging of prostate cancer patients. The aim of the current study was to evaluate the potential added value of 68 Ga PSMA PET-CT imaging in initial staging of low, intermediate and high risk prostate cancer patients and the clinical impact of oligometastatic disease.

2. Materials and methods

Patients with newly diagnosed prostate cancer were referred for initial staging by Ga-68 PSMA PET/CT between December 2018-September 2020. Patients' data diagnosed with biopsy proven newly diagnosed prostate cancer and underwent 68Ga PSMA PET-CT were selected retrospectively. A total of 750 68Ga PSMA PET-CT scans were performed for initial staging, restaging, detection of suspected recurrence and therapy response in prostate cancer patients in this period. Patients with low, intermediate and high risk prostate cancer referred for initial staging of prostate cancer were included in the current study. PSA values, Gleason scores, PET/CT and conventional imaging results were noted. According to pathological reports and PSA values, patients were divided into three groups as low, intermediate and high risk.

3. Imaging protocol

After 68 Ga was filtered from the Ge-68/Ga-68 generator system, it was binded with the help of a synthesis unit and quality controls were performed. 68Ga-PSMA-11(Glu-NH-CO-NH-Lys-(Ahx)-[68Ga(HBED-CC)]) was used as the PSMA ligand. 68 Ga PET/CT scans were obtained 60 min (range: 50-100 min) after injection of 185 MBq (5 mCi) 68 Ga PSMA using an integrated scanner (Siemens, Biograph True Point 6 PET/CT, Germany). The patients were instructed to void prior to acquisition. Early or post diuretic late imaging for evaluating the pelvic region was sometimes used if necessary. A whole-body CT scan was performed without intravenous contrast administration with 130 kV, 50 mAs, a pitch of 1.5, a section thickness of 5 mm, and a field of view of 70 cm. CT data were used for attenuation correction. A PET scan was performed immediately after an unenhanced CT scan, and acquired from the skull base to the upper thigh with a 2-min acquisition per bed position using a three-dimensional acquisition mode. Maximal standardized uptake values (SUVmax) were obtained for all primary and metastatic lesions.

4. Diagnostic criteria for metastases

Any lesion inside or outside the prostate gland showing high tumor to background activity compared to surrounding tissue was accepted as a pathological site, whereas normal and physiological uptake regions were excluded. Histopathology and follow-up clinical and radiological information after PET/CT scanning served as the standard of reference.

5. Image analysis

PET/CT images were viewed in the coronal, axial, and sagittal sections. The maximum standarduptake value (SUVmax) of lesions was calculated on PET/CT using region of interest (ROI), which included at least two-thirds of the nodular lesions. The partial volume effect was minimized in this way. The regions were drawn by generating sphere circles. The quantitative uptake values of 68Ga (SUVmax) in the nodules ROIs were semiautomatically calculated using workstations (Siemens).

6. Statistical analysis

Statistical analysis was carried out with SPSS software (SPSS Inc., Chicago, Illinois, USA). A P value of less than 0.05 was considered statistically significant.

7. Results

There were 176 prostate cancer patients referred for first-line imaging with Ga-68 PSMA PET/CT between December 2018-September 2020. Patients were divided into three groups as low, intermediate and high risk according to biopsy findings, radiological imaging findings and PSA level. Low risk patients determined as T1-T2 tumour, PSA < 10 ng/ml and Gleason score (GS): < 7, intermediate risk cT2b, PSA: 10-20 ng/ml, GS:7 and high risk cT2c, PSA> 20 ng/ml and GS:> 20.

There were a total of 27 low risk, 35 intermediate risk and 114 high risk patients included in the study. Mean age was 64 (range: 51-72), 68 (range<. 54-85) and 69 (range: 49-88) in low, intermediate and high risk patients, respectively.

All low risk patients had prostate adenocancer pathology and had Ga-68 PSMA avidity in the primary tumour. Primary prostate lesion Ga-68 PSMA uptake was at single focus in 21/27 (77.8 %) patients, whereas multifocal in 6 /27 (22.2%) patients. Mean SUVmax value in primary prostate lesion was 16.6 (range: 3-62) in low risk patients. A total of 7/27 patients were metastatic in low risk group (25.9 %). Treatment approach was changed in these patients. Ga-68 avid lesions were detected only in primary prostate tumour in 20 of 27 low risk patients. Additional bone metastases in 5 of 27, abdominopelvic lymph nodes in 1 patient and both bone metastases and abdominopelvic lymph nodes in 1 of 27 patients. Six of the 7 patients with metastases were oligometastatic (n=6/27: 22%). Only one patient had a high number of metastases (n=1/27: 3.7 %). Results of low risk patients were demonstrated in Table I. Non-prostate cancer caused Ga-68 PSMA avid 2x3.5 cm (SUVmax: 27) left submandibular mass was detected in one patient. Biopsy of non-Ga-68 PSMA avid abdominal lymphadenopathies in another patient were compatible with lymphangioma. Anterior mediasten mass detected on Ga-68 PSMA PET-CT was secondary to thymoma in a different patient. Solid organ metastases were detected in none of the low risk patients.

Table 1. Ga-68 PSMA PET-CT results in low risk patients.

Region	Patient number	% (n)
Organ-confined disease (only prostate region)	20	74 (20/27)
Loco-regional region	3	11 (3/27)
Abdominopelvic LN	*2	7. (2/27)
Bone Metastases	*6	18.5 (6/27)
Distant visseral metastases	0	0

***One patient had both lymph node and bone metastases.**

Thirty-five intermediate risk group patients requested Ga-68 PSMA PET-CT initial imaging for suspected metastases. All intermediate risk patients had prostate adenocancer pathology and had Ga-68 PSMA avidity in the primary tumor, except three of which had total prostatectomy before imaging. None of the three operated patients had metastases on Ga-68 PSMA PET-CT imaging. Primary prostate lesion Ga-68 PSMA uptake was at single focus in 20/32 patients (62.5%), whereas multifocal in 12 /32 patients (37.5%). The mean SUVmax value in the primary prostate lesion was 25.8 (range: 3-112) in intermediate risk patients. A total of 11/35 patients were metastatic in intermediate risk group (31.4 %). Treatment strategy was changed in these patients. Ga-68

avid lesions were detected only in primary prostate tumour in 21 of 32 non-operated intermediate risk patients. A total of 11/35 (31.4 %) patients had metastases. Additional bone metastases in 2 of 35, abdominopelvic lymph nodes in 6 patients and both bone metastases and abdominopelvic lymph nodes in 3 of 35 patients. Eight of the 11 patients with metastases were oligometastatic (n=8/35: 22.8%). One of the oligometastatic prostate cancer patients had secondary primary metastatic lung cancer. A non-prostate cancer cause, Ga-68 PSMA avid lung mass 4x4.5 cm (SUVmax: 5) and mediastinal lymphadenopathies were detected in this patient. Biopsy of lung mass demonstrating Ga-68 PSMA avidity was compatible with lung adenocancer. Three patients had a high number of metastases (n=3/35: 8.6 %). Results of intermediate risk patients were demonstrated in Table II. Solid organ metastases were not detected any of the intermediate risk patients.

Table 2. Ga-68 PSMA PET-CT results in intermediate risk patients.

Region	Patient number	% (n)
Organ-confined disease (only prostate region)	*21	65.6 (21/32)
Loco-regional region	5	15.6 (5/32)
Abdominopelvic LN	**9	25.7 (9/35)
Bone Metastases	**5	14.3 (5/35)
Distant visseral metastases	0	0

***3 of 35 patients had prostatectomy before imaging. None of them had residual activity in the operation region.**

**** 3 of 11 metastatic patients had both abdominopelvic lymph nodes and bone metastases.**

There were 114 high risk group patients requested Ga-68 PSMA PET-CT initial imaging for suspected metastases. The majority of the high risk patients (n: 109/114) had prostate adenocancer pathology, whereas 2 patients had ductal adenocancer and 3 patients had neuroendocrine prostate cancer pathology. All of the patients had Ga-68 PSMA avidity in the primary tumor except 1 of which had total prostatectomy before imaging. The patient with total prostatectomy had no metastases on Ga-68 PSMA PET-CT imaging. In addition to prostate cancer, 7/114 patients had a diagnosis of secondary malignancy, including renal cell cancer (RCC), multiple myeloma (MM), colon cancer, sarcoma, lung cancer, stomach cancer, basal cell and squamous cell scin cancer. Some of these second malignancies such as colon, lung, stomach cancer, RCC and MM had Ga-68 PSMA affinity. Primary prostate lesion Ga-68 PSMA uptake was at single focus in 49/113 patients (44 %), whereas multifocal or a mass in 64 /113 patients (56%). Mean SUVmax value in primary prostate lesion was 35.2 (range: 4-261) in high risk patients. A total of 78/114 patients were metastatic in high risk group (68.4 %), whereas 36/114 were nonmetastatic (31.6 %). Ga-68 avid lesions were detected only in primary prostate tumour in 35 of 113 non-operated high risk patients. A total of 78/114 (68.4 %) patients had metastases. A total of 18 patients were oligometastatic (15.7 %), and 60 of 114 patients were multiple metastatic (52.6 %). Additional bone metastases in 50 of 78, abdominopelvic lymph nodes in 60 patients, mediastinal, inguinal, supra-infraclavicular, and axillary lymph nodes in 27 patients, lung metastases in 7, liver metastases in 2, penil metastases in 2 and surrenal metastases in 1 of the 78 metastatic patients. The most common metastatic regions were bone and abdominopelvic lymph nodes. Superscan pattern was detected in 3 of 50 patients with bone metastases. Results of high risk patients were demonstrated in Table III. Solid organ metastases were detected in 12 high risk patients.

Table 3. Ga-68 PSMA PET-CT results in high risk patients.

Region	Patient number	%
Organ-confined disease (only prostate region)	35	31 (35/113)
Loco-regional region	23	20 (23/113)
Abdominopelvic LN	60	52.6 (60/114)
Bone Metastases	50	43.8 (50/114)
Non-abdominopelvic LN	27	23.7 (27/114)
Distant visseral metastases	12	10.5 (12/114)

In our study in all groups of patients benign and some malignant lesions were detected incidentally including accessory spleen, lipoma, fibroma, viral pneumonia, benign and malignant skin lesions, liver hemangioma, renal cyst, thymoma, asbestosis, lymphangioma, benign lung nodules mediastinal and axillary reactive lymph nodes, had no, low or medium uptake with 68 Ga PSMA.

Figure 1-4 demonstrate patients with similar PSA levels but different Ga-68 PSMA findings and Table IV and V demonstrates a comparison of all risk group patients.

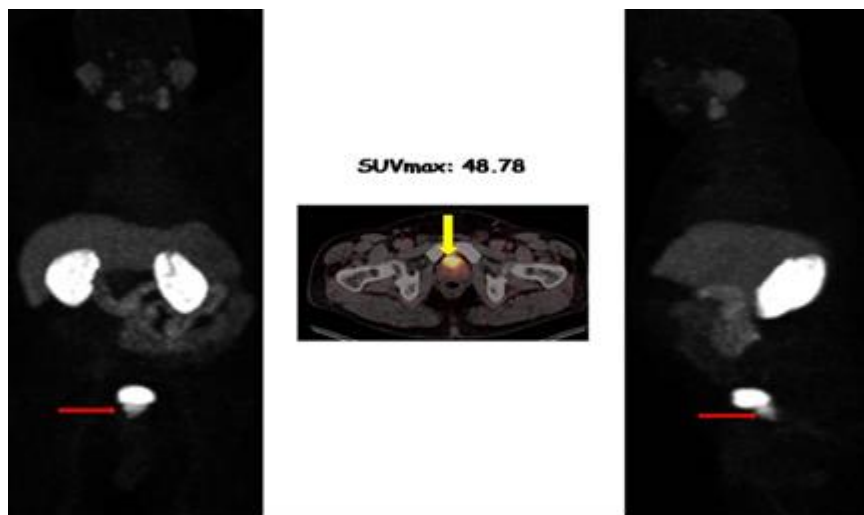


Figure 1. Coronal and sagittal MIP (Maximum Intensity Projection Image) and axial PET-CT fusion images in 60 years of newly diagnosed prostate cancer patients. Gleason score 10 (5+5), prognostic grade 5 and perineural invasion were detected on pathological examination. The patient with PSA level 39, underwent Ga-68 PSMA imaging for initial staging because of suspected metastases. On Ga-68 PSMA PET/CT imaging hypermetabolic (SUVmax: 48) 3.5X3 cm primary prostate mass was detected. There was any other metastatic region despite the high PSA level. After radical prostatectomy and lymph node dissection all lymph nodes were reactive in accordance with Ga-68 PSMA PET/CT results.

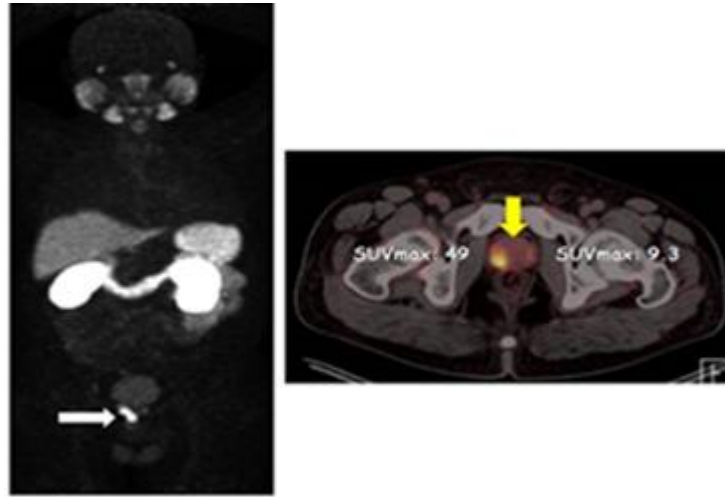


Figure 2. MIP and axial fusion images of a 59 year of Gleason scor 7 (3+4) prostate cancer patient with PSA level 22 demonsrates only primary prostate multifocal Ga-68 PSMA uptake.

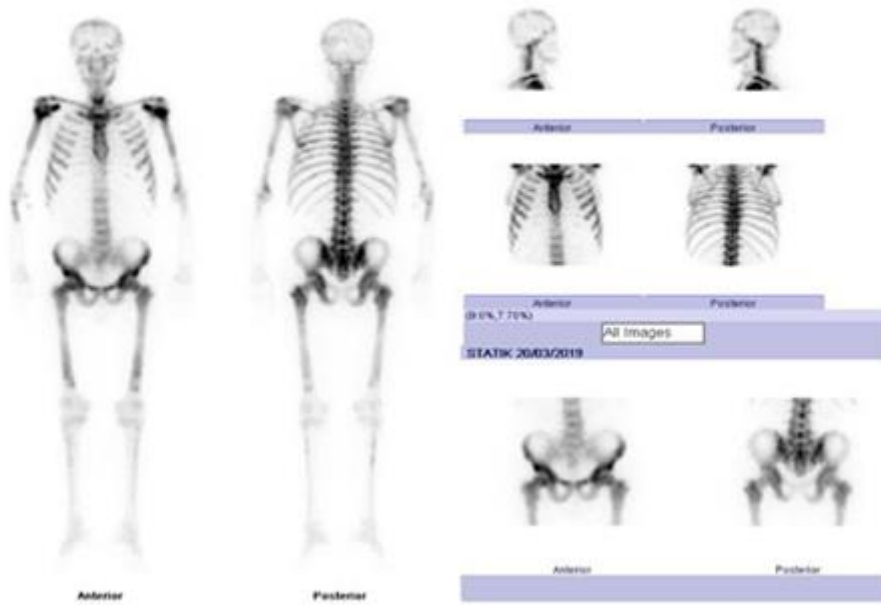

Figure 3. Superscan pattern on bone scintigraphy in a 69 year old prostate cancer patient with PSA level >25, Gleason score: 10 (5+5), prognostic grade: 5 and perineural invasion.

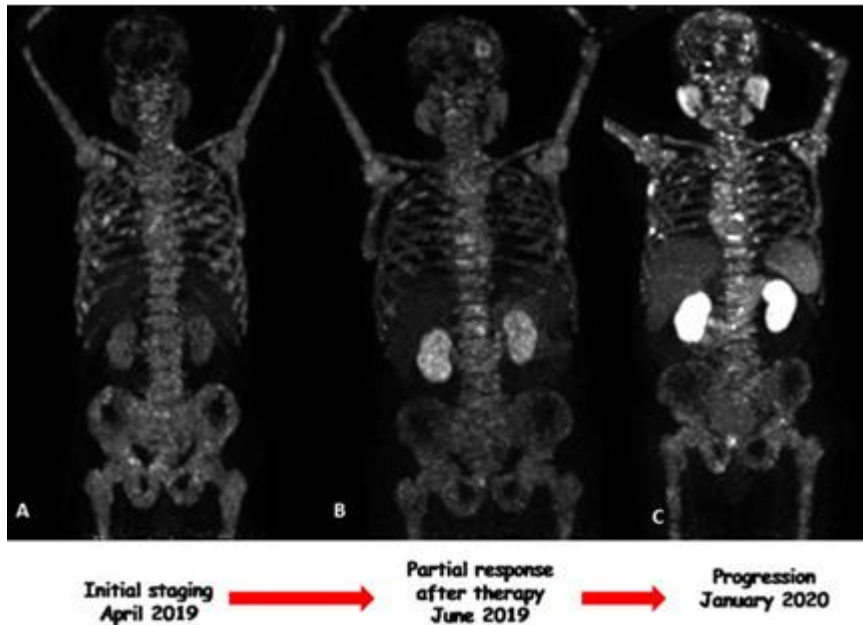


Figure 4. Superscan patterns on serial Ga-68 PSMA images with changing uptake values after therapy of the same patient on first line image (A), posttherapy (B) and restaging (C)

Table 4. Ga-68 PSMA PET-CT results in all risk patients.

	LOW (n: 27)	INTERMEDIATE (n: 35)	HIGH (n: 114)
<i>RISK GROUP</i>	LOW (n: 27)	INTERMEDIATE (n: 35)	HIGH (n: 114)
<i>Primary lesion mean SUVmax</i>	16.6 (range: 3-62)	25.8 (range: 3-112)	35.2 (range: 4-261)
<i>Metastases (%)</i>	25.9	31.4	68.4
<i>Oligometastases (%)</i>	22	22.8	15.7
<i>Multipl Metastases (%)</i>	3.7	8.6	52.6

The rate of oligometastases was the same in low and intermediate risk groups, although all other parameters increased from low to high risk patients. The rate of multifocality, primary prostate lesion mean SUVmax value, solid organ metastases and the likelihood of multiple metastases increased from low to high risk patients as expected. Multiple metastases were detected in 4 of 62 (27 and 35) total low and intermediate risk patients. Oligometastases were detected with a relatively high rate in low and intermediate risk group patients.

Table 5. Ga-68 PSMA PET-CT results in all risk metastatic patients.

	LOW	INTERMEDIATE	HIGH
<i>LOW</i>	20 (74)	6 (22.3)	1 (3.7)
<i>INTERMEDIATE</i>	21 (65.6)	8 (22.8)	3 (8.7)
<i>HIGH</i>	35 (31)	18 (15.7)	60 (52.5)
<i>Total</i>	76 (44: 76/*172)	32 (18:18/176)	64 (36:36/176)

*Non-operated total patients

8. Discussion

Prostate cancer is one of the most commonly diagnosed cancers in men and one of the leading causes of cancer death. Accurate staging for effective therapeutic options is critical for patient management. Organ confined stage or oligometastatic stage may change the treatment strategy. A total of 76 patients had organ confined disease in all groups of total nonoperated patients (76/172: 44.2 %), whereas 96/176 of all patients had metastases. The treatment approach has changed according to these results.

The staging of patients with prostate cancer using conventional imaging methods such as MRI, CT and bone scintigraphy is limited because of low sensitivity for metastatic disease, especially in low PSA levels. Ga-68 PSMA PET/CT is a new, very sensitive and non-invasive imaging method in prostate cancer patients targeting a transmembrane protein called PSMA. Imaging with Ga-68 PSMA (Prostate specific membrane antigen) has more sensitivity than other conventional methods, especially in biochemical relapse. However, data on using Ga-68 PSMA (Prostate specific membrane antigen) as an initial staging-first line imaging modality is limited. PSMA (glutamate carboxypeptidase II) is a cell surface glycoprotein. The specific presence of this enzyme in the prostate gland, has made it an ideal theranostic target in the diagnosis and treatment of prostate cancer (11). The results of studies with 68 Ga PSMA are exceptionally good compared to other imaging methods. Many labeled PSMA antibody derivatives are developed for diagnosing and treating prostate cancers by targeting the PSMA antigen in nuclear medicine applications (12,13). The likelihood of locoregional, abdominopelvic lymph nodes or bone metastases increases in patients with especially high-risk diseases. High-risk disease has been defined as patients with Gleason score > 7, PSA > 20 ng/ ml, clinical stage T2c and T3a. Until now few studies demonstrate the superiority of Ga-68 PSMA imaging compared to conventional imaging for the initial staging of prostate cancer (5, 14-16). Although the number of patients in the low risk group was small, one fourth of the patients in this group had metastasis, mostly oligometastasis in our study group.

SUVmax in the primary tumor was correlated significantly with PSA levels and patient risk group. Mean SUVmax values of the primary prostate lesion were 16.6 %, 25.8 % and 35.2 % in low, intermediate and high risk patients, respectively. Oligometastases were detected in low and intermediate groups in similar proportions and slightly less in high risk patients (22 %, 22.8 % and 15.7 % in low, intermediate and high risk patients respectively), whereas multiple metastases were detected significantly higher in high risk group patients (3.7 %, 8.6 % and 52.6 %, in the low, intermediate and high risk patients respectively. None of the patients in low and intermediate risk group had solid organ distant metastases in our patients.

The majority of all patients, [97% (n: 171/176)] had prostate adenocancer pathology, whereas two patients had ductal adenocancer and three patients had neuroendocrine prostate cancer pathology in the high risk group. These patients had Ga-68 PSMA avidity in both primary lesion and metastases. However, patients with ductal adenocancer pathology had more FDG avidity from Ga-68 PSMA. Treatment follow up was suggested to be complete with FDG PET-CT instead of Ga-68 PSMA in these patients.

A total of 10 patients [5.7% (10/176)] had second malignancies known before imaging or newly detected at the time of Ga-68 PSMA examination, incidentally. A lung mass and mediastinal metastatic lymphadenopathies were incidentally detected in a low risk oligometastatic prostate cancer patient.

Giesel et al. compared Ga-68 PSMA PET-CT imaging findings with 3D volumetric CT findings (17). As a CT finding, 8 mm or above is suspicious for positivity. In this study, 2.4 mm size lymph nodes could be detected with Ga-68 PSMA PET-CT. Only 36 percent of lymph nodes were larger than 8 mm. The clinical impact of the improved sensitivity of Ga-68 PSMA PET/CT imaging on overall survival or patient management is not known. Most of the metastatic lymph nodes detected on Ga-68 PSMA images in the current study, especially in the low and intermediate oligometastatic group of patients were less than 1 cm. It should be kept in mind that approximately 5% of all prostate cancers may not have an overexpression of PSMA release (5, 18).

Recently, exciting results were published on a proPSMA clinical multicentre trial on the role of Ga-68 PSMA PET/CT on primary staging. The researchers found a lower sensitivity (38% [24-52] vs 85% [74-96]) and specificity (91% [85-97] vs 98% [95-100]) for conventional imaging compared with PSMA PET-CT. They found high reporter agreement for Ga-68 PSMA PET-CT ($\kappa=0.87$ for nodal and $\kappa=0.88$ for distant metastases). In patients who underwent second-line image, management change occurred in seven (5%) of 136 patients following conventional imaging, and 39 (27%) of 146 following PSMA PET-CT. PSMA PET-CT was reported as being a suitable replacement for conventional imaging, providing superior accuracy, to the combined findings of CT and bone scanning (19).

The addition of early imaging significantly improved the overall detection rate of PSMA-avid lesions ($p = 0.039$) in a recent study (20). The authors recommend early imaging in addition to the standard imaging in Ga-68 PSMA PET/CT, particularly in patients presenting for restaging of prostate cancer. We used early or postdiuretic late imaging to evaluate pelvic region if necessary and observed advantage in these additional images.

Patients with newly diagnosed biopsy-proven prostate cancer who had been staged with a conventional staging protocol including bone scintigraphy and additionally underwent [⁶⁸Ga] PSMA PET/CT were evaluated retrospectively in another recent study (21). Sixty-four patients with intermediate and high-risk prostate cancer were evaluated. The authors found that with additional information of PET/CT, nodal status was upstaged 23%, and downstaged by 9%. Metastases status was upstaged in 13%, and downstaged in 23%. Ga68 PSMA a valuable tool for prostate cancer staging in another report by Ayan A et al. (22).

As a result, Ga-68 PSMA PET-CT imaging in newly diagnosed prostate cancer patients, even in low risk patients, was found to be quite useful in the current study.

9. Conclusions

Oligometastases rate was the same in low and intermediate risk groups. The oligometastatic disease changes treatment strategy. Although the expectation of metastases was low in low-risk patients, the rate of metastasis in Ga-68 PSMA examination was quite high in patients in the low-risk group. Additionally, second primary malignancies were detected incidentally in some patients including low risk group. These essential results indicate that Ga-68 PSMA imaging should be done in all risk groups as a first-line imaging modality. This finding should be supported by other studies with a large number of patients

Conflict of Interest

No conflict of interest was declared by the authors.

Author Contributions

Concept: P.P.O.; Design: P.P.O., G.Y.; Supervision: P.P.O., Z.P.K., V.E., M.B., M.T., E.A.; Funding: P.P.O., Z.S.S.; Data Collection and/or Processing: P.P.O.; Analysis and/or Interpretation: P.P.O.; Literature Review: P.P.O.; Writer: P.P.O., G.Y.

REFERENCES

1. Perera, M., Papa, N., Christidis, D., Wetherell, D., Hofman, M. S., Murphy, D. G., Bolton, D., & Lawrentschuk, N. (2016). Sensitivity, Specificity, and Predictors of Positive 68Ga-Prostate-specific Membrane Antigen Positron Emission Tomography in Advanced Prostate Cancer: A Systematic Review and Meta-analysis. *European urology*, 70(6), 926–937. <https://doi.org/10.1016/j.eururo.2016.06.021>
2. Mottet, N., Bellmunt, J., Bolla, M., Briers, E., Cumberbatch, M. G., De Santis, M., Fossati, N., Gross, T., Henry, A. M., Joniau, S., Lam, T. B., Mason, M. D., Matveev, V. B., Moldovan, P. C., van den Bergh, R., Van den Broeck, T., van der Poel, H. G., van der Kwast, T. H., Rouvière, O., Schoots, I. G., ... Cornford, P. (2017). EAU-ESTRO-SIOG Guidelines on Prostate Cancer. Part 1: Screening, Diagnosis, and Local Treatment with Curative Intent. *European urology*, 71(4), 618–629. <https://doi.org/10.1016/j.eururo.2016.08.003>
3. Heidenreich, A., Bastian, P. J., Bellmunt, J., Bolla, M., Joniau, S., van der Kwast, T., Mason, M., Matveev, V., Wiegel, T., Zattoni, F., Mottet, N., & European Association of Urology (2014). EAU guidelines on prostate cancer. part 1: screening, diagnosis, and local treatment with curative intent-update 2013. *European urology*, 65(1), 124–137. <https://doi.org/10.1016/j.eururo.2013.09.046>
4. Larson, S. M., Morris, M., Gunther, I., Beattie, B., Humm, J. L., Akhurst, T. A., Finn, R. D., Erdi, Y., Pentlow, K., Dyke, J., Squire, O., Bornmann, W., McCarthy, T., Welch, M., & Scher, H. (2004). Tumor localization of 16beta-18F-fluoro-5alpha-dihydrotestosterone versus 18F-FDG in patients with progressive, metastatic prostate cancer. *Journal of nuclear medicine : official publication, Society of Nuclear Medicine*, 45(3), 366–373.
5. Maurer, T., Gschwend, J. E., Rauscher, I., Souvatzoglou, M., Haller, B., Weirich, G., Wester, H. J., Heck, M., Kübler, H., Beer, A. J., Schwaiger, M., & Eiber, M. (2016). Diagnostic Efficacy of (68)Gallium-PSMA Positron Emission Tomography Compared to Conventional Imaging for Lymph Node Staging of 130 Consecutive Patients with Intermediate to High Risk Prostate Cancer. *The Journal of urology*, 195(5), 1436–1443. <https://doi.org/10.1016/j.juro.2015.12.025>
6. Dewes, S., Schiller, K., Sauter, K., Eiber, M., Maurer, T., Schwaiger, M., Gschwend, J. E., Combs, S. E., & Habl, G. (2016). Integration of (68)Ga-PSMA-PET imaging in planning of primary definitive radiotherapy in prostate cancer: a retrospective study. *Radiation oncology (London, England)*, 11, 73. <https://doi.org/10.1186/s13014-016-0646-2>
7. Shakespeare T. P. (2015). Effect of prostate-specific membrane antigen positron emission tomography on the decision-making of radiation oncologists. *Radiation oncology (London, England)*, 10, 233. <https://doi.org/10.1186/s13014-015-0548-8>
8. Roach, P. J., Francis, R., Emmett, L., Hsiao, E., Kneebone, A., Hruby, G., Eade, T., Nguyen, Q. A., Thompson, B. D., Cusick, T., McCarthy, M., Tang, C., Ho, B., Stricker, P. D., & Scott, A. M. (2018). The Impact of 68Ga-PSMA PET/CT on Management Intent in Prostate Cancer: Results of an Australian Prospective Multicenter Study. *Journal of nuclear medicine : official publication, Society of Nuclear Medicine*, 59(1), 82–88. <https://doi.org/10.2967/jnumed.117.197160>
9. Fendler, W. P., Schmidt, D. F., Wenter, V., Thierfelder, K. M., Zach, C., Stief, C., Bartenstein, P., Kirchner, T., Gildehaus, F. J., Gratzke, C., & Faber, C. (2016). 68Ga-PSMA PET/CT Detects the Location and Extent of Primary Prostate Cancer. *Journal of nuclear medicine : official publication, Society of Nuclear Medicine*, 57(11), 1720–1725. <https://doi.org/10.2967/jnumed.116.172627>

10. Kuten, J., Mabweesh, N. J., Lerman, H., Levine, C., Barnes, S., & Even-Sapir, E. (2019). Ga-PSMA PET/CT Staging of Newly Diagnosed Intermediate- and High-Risk Prostate Cancer. *The Israel Medical Association journal : IMAJ*, 21(2), 100–104.
11. Sweat, S. D., Pacelli, A., Murphy, G. P., & Bostwick, D. G. (1998). Prostate-specific membrane antigen expression is greatest in prostate adenocarcinoma and lymph node metastases. *Urology*, 52(4), 637–640. [https://doi.org/10.1016/s0090-4295\(98\)00278-7](https://doi.org/10.1016/s0090-4295(98)00278-7)
12. Agus, D. B., Golde, D. W., Sgouros, G., Ballangrud, A., Cordon-Cardo, C., & Scher, H. I. (1998). Positron emission tomography of a human prostate cancer xenograft: association of changes in deoxyglucose accumulation with other measures of outcome following androgen withdrawal. *Cancer research*, 58(14), 3009–3014.
13. Liu, H., Moy, P., Kim, S., Xia, Y., Rajasekaran, A., Navarro, V., Knudsen, B., & Bander, N. H. (1997). Monoclonal antibodies to the extracellular domain of prostate-specific membrane antigen also react with tumor vascular endothelium. *Cancer research*, 57(17), 3629–3634.
14. Herlemann, A., Wenter, V., Kretschmer, A., Thierfelder, K. M., Bartenstein, P., Faber, C., Gildehaus, F. J., Stief, C. G., Gratzke, C., & Fendler, W. P. (2016). 68Ga-PSMA Positron Emission Tomography/Computed Tomography Provides Accurate Staging of Lymph Node Regions Prior to Lymph Node Dissection in Patients with Prostate Cancer. *European urology*, 70(4), 553–557. <https://doi.org/10.1016/j.eururo.2015.12.051>
15. Hijazi, S., Meller, B., Leitsmann, C., Strauss, A., Meller, J., Ritter, C. O., Lotz, J., Schildhaus, H. U., Trojan, L., & Sahlmann, C. O. (2015). Pelvic lymph node dissection for nodal oligometastatic prostate cancer detected by 68Ga-PSMA-positron emission tomography/computerized tomography. *The Prostate*, 75(16), 1934–1940. <https://doi.org/10.1002/pros.23091>
16. Pyka, T., Okamoto, S., Dahlbender, M., Tauber, R., Retz, M., Heck, M., Tamaki, N., Schwaiger, M., Maurer, T., & Eiber, M. (2016). Comparison of bone scintigraphy and 68Ga-PSMA PET for skeletal staging in prostate cancer. *European journal of nuclear medicine and molecular imaging*, 43(12), 2114–2121. <https://doi.org/10.1007/s00259-016-3435-0>
17. Giesel, F. L., Fiedler, H., Stefanova, M., Sterzing, F., Rius, M., Kopka, K., Moltz, J. H., Afshar-Oromieh, A., Choyke, P. L., Haberkorn, U., & Kratochwil, C. (2015). PSMA PET/CT with Glu-urea-Lys-(Ahx)-[⁶⁸Ga(HBED-CC)] versus 3D CT volumetric lymph node assessment in recurrent prostate cancer. *European journal of nuclear medicine and molecular imaging*, 42(12), 1794–1800. <https://doi.org/10.1007/s00259-015-3106-6>
18. Budäus, L., Leyh-Bannurah, S. R., Salomon, G., Michl, U., Heinzer, H., Huland, H., Graefen, M., Steuber, T., & Rosenbaum, C. (2016). Initial Experience of (68)Ga-PSMA PET/CT Imaging in High-risk Prostate Cancer Patients Prior to Radical Prostatectomy. *European urology*, 69(3), 393–396. <https://doi.org/10.1016/j.eururo.2015.06.010>
19. Hofman, M. S., Lawrentschuk, N., Francis, R. J., Tang, C., Vela, I., Thomas, P., Rutherford, N., Martin, J. M., Frydenberg, M., Shakher, R., Wong, L. M., Taubman, K., Ting Lee, S., Hsiao, E., Roach, P., Nottage, M., Kirkwood, I., Hayne, D., Link, E., Marusic, P., ... proPSMA Study Group Collaborators (2020). Prostate-specific membrane antigen PET-CT in patients with high-risk prostate cancer before curative-intent surgery or radiotherapy (proPSMA): a prospective, randomised, multicentre study. *Lancet (London, England)*, 395(10231), 1208–1216. [https://doi.org/10.1016/S0140-6736\(20\)30314-7](https://doi.org/10.1016/S0140-6736(20)30314-7)
20. Barakat, A., Yacoub, B., Homsy, M. E., Saad Aldine, A., El Hajj, A., & Haidar, M. B. (2020). Role of Early PET/CT Imaging with 68Ga-PSMA in Staging and Restaging of Prostate Cancer. *Scientific reports*, 10(1), 2705. <https://doi.org/10.1038/s41598-020-59296-6>
21. Donswijk, M. L., van Leeuwen, P. J., Vegt, E., Cheung, Z., Heijmink, S., van der Poel, H. G., & Stokkel, M. (2020). Clinical impact of PSMA PET/CT in primary prostate cancer compared to conventional nodal and distant staging: a retrospective single center study. *BMC cancer*, 20(1), 723. <https://doi.org/10.1186/s12885-020-07192-7>
22. Asli Ayan, Sumeyye Alkan and Bengül Gunalp. The Value of Ga-68 PSMA PET /CT in Primary Staging of Prostate Cancer. *Journal of Nuclear Medicine* May 2018, 59 (supplement 1) 1450.

